

[文章编号] 1000-1182(2009)01-0115-02

## 上颌第二磨牙四根管1例

张庆福 刘国勤 赵海军 陈骏 张新海

(解放军第411医院 南京军区口腔专科中心, 上海 200081)

[摘要] 上颌第二磨牙四根管发生率低, 且主要类型为近颊双根管的四根管, 腭侧双根管的四根管十分罕见。本文报道1例腭侧双根管的四根管上颌第二磨牙。

[关键词] 上颌第二磨牙; 根管; 根管治疗

[中图分类号] R781.05 [文献标识码] B

**Maxillary second molar with two buccal and two lingual root canals: A case report** ZHANG Qing-fu, LIU Guo-qin, ZHAO Hai-jun, CHEN Jun, ZHANG Xin-hai. (Stomatological Center of Nanjing Military Command, The 411 Hospital of PLA, Shanghai 200081, China)

**[Abstract]** Incidence rate of 4 root canals in maxillary second molar is very low and most molars have only two mesiobuccal root canals. The emergence of 4 root canals in maxillary second molar with two lingual root canals is especially rare. A case of 4 root canals maxillary second molar with two lingual root canals was successfully treated and reported in this article.

**[Key words]** maxillary second molar; root canal; root canal therapy

临床报道上颌第二磨牙四根管的发生率约为8.1%, 主要是近颊双根管型<sup>[1]</sup>, 腭侧双根管的四根管十分罕见。解放军第411医院成功治疗1例腭侧双根管型四根管上颌第二磨牙, 现报道如下。

### 1 病例报告

患者余某某, 女, 23岁, 2007年10月因右上后牙疼痛伴咬物痛1周来解放军第411医院南京军区口腔专科中心就诊。患者2年前发现右上后牙龋坏, 一直未作治疗。1周前右上后龋坏牙齿出现疼痛和咬物疼痛, 影响咀嚼。

牙体检查: 右侧上颌第二磨牙牙冠较大, 骀面巨大龋洞, 冠部牙体呈空壳状, 洞深超过1 cm, 洞底不清晰, 洞壁软龋较多, 洞底探及较厚实软组织, 探诊疼痛, 叩诊略有不适, 冷热无反应。牙体检查无法确切判断洞底是穿髓还是髓室底穿通。X线片示右侧上颌第二磨牙髓室底完整, 位置较低, 根管系统不甚清晰, 右上第三磨牙阻生。诊断: 右侧上颌第二磨牙慢性牙髓炎。

治疗: 局部麻醉下完整揭开髓室顶, 去尽软化

牙本质, 挖除冠髓, 见到4个位置散开分布的根管口, 颊舌侧各2个, 近中2个根管口颊舌向距离略大, 4个根管口向远中呈梯形分布(图1)。术中插针X线片显示, 右上颌第二磨牙有近中颊侧、远中颊侧、近中腭侧、远中腭侧4个根管, 均较为粗大, 近中腭侧根偏向近中, 其余3个根管略向远中(图2)。根管顺利地清理扩大至40号根管锉, 清理扩大过程中反复双氧水、生理盐水交替冲洗, 根管干燥后氧化锌丁香油糊剂加牙胶尖利用侧压法完成根管充填, 洞室暂封, 观察1周后垫底利用髓室固位完成牙体修复, 最后作烤瓷全冠保护性修复。

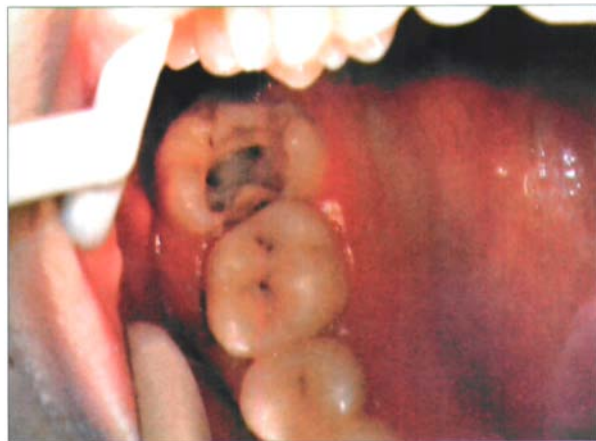


图1 髓室底4个根管口清晰

Fig 1 Four root canal orifices in pulp cavity

[收稿日期] 2008-03-14; [修回日期] 2008-05-20

[作者简介] 张庆福(1968-), 男, 安徽人, 副主任医师, 博士

[通讯作者] 张庆福, Tel: 021-51664178

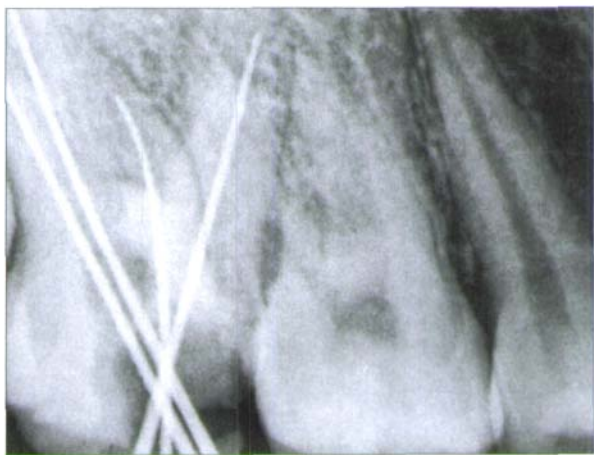

图2 术中X线片显示4个根管

Fig 2 X-ray showing 4 root canals

## 2 讨论

良好的根管扩大、消毒和充填是根管治疗的必要步骤。上颌第二磨牙髓室变异、髓室底位置较深及靠后使根管治疗的操作空间和视野不佳,同时根管的融合或变异更增加了根管的治疗难度。治疗此类患牙时应谨慎操作,反复、仔细探查根管,防止发生根管的遗漏,同时避免髓室底穿孔,提高根管治疗的成功率<sup>[2]</sup>。本例患牙由于龋洞较深,髓室底

较低,冠髓质地韧厚,仅靠牙体检查对穿髓还是髓室底穿通不能明确判断,最后通过X线片才确定了髓室底的完整。这提示临床上不能仅靠牙体检查来判断髓室底是否完整,而应作进一步的X线检查。

腭侧双根管型四根管上颌第二磨牙十分罕见。本例患者的4个根管口均较为清晰,根管粗大,但近中腭侧根过于向近中偏斜,髓室底较低,根管清理和充填具有一定的难度。由于本例患牙的髓室较深,完成根管充填后利用髓室固位完成牙体修复,通过全冠保护性修复使得患牙得以完好保留。

## 【参考文献】

- [1] 王效平, 王忠桂, 叶荣, 等. 上颌第二磨牙根管的临床观察[J]. 华西口腔医学杂志, 2005, 23(5): 453-454.  
WANG Xiao-ping, WANG Zhong-gui, YE Rong, et al. Clinical investigation of root canal system of maxillary second molar[J]. West China J Stomatol, 2005, 23(5): 453-454.
  - [2] 黄定明, 谭红. 上颌第二磨牙腭根及根管变异1例报告[J]. 华西口腔医学杂志, 2005, 23(4): 356-357.  
HUANG Ding-ming, TAN Hong. Variation of palatal root and root canal of maxillary second molar: A case report[J]. West China J Stomatol, 2005, 23(4): 356-357.
- (本文编辑 李彩)
- 
- (上接第106页)
- [2] 汪昆, 李德华. 牙种植体稳定性的评价方法[J]. 中国口腔种植学杂志, 2005, 10(2): 99-101.  
WANG Kun, LI De-hua. The evaluation methodology of the stability of dental implants[J]. Chin J Oral Implant, 2005, 10(2): 99-101.
  - [3] Tada S, Stegaroiu R, Kitamura E, et al. Influence of implant design and bone quality on stress/strain distribution in bone around implants: A 3-dimensional finite element analysis[J]. Int J Oral Maxillofac Implants, 2003, 18(3): 357-368.
  - [4] Kohal RJ, Weng D, Bächle M, et al. Loaded custom-made zirconia and titanium implants show similar osseointegration: An animal experiment[J]. J Periodontol, 2004, 75(9): 1262-1268.
  - [5] Salata LA, Burgos PM, Rasmusson L, et al. Osseointegration of oxidized and turned implants in circumferential bone defects with and without adjunctive therapies: An experimental study on BMP-2 and autogenous bone graft in the dog mandible[J]. Int J Oral Maxillofac Surg, 2007, 36(1): 62-71.
  - [6] Botticelli D, Berglundh T, Persson LG, et al. Bone regeneration at implants with turned or rough surfaces in self-contained defects. An experimental study in the dog[J]. J Clin Periodontol, 2005, 32(5): 448-455.
  - [7] Demirel M, Dereboy F, Ozturk A, et al. Arthroscopically assisted intra-articular lateral femoral condyle fracture surgery[J]. Arthroscopy, 2006, 22(6): 690.
  - [8] 时宏富, 蔡贤华, 汪国栋, 等. 股骨髁冠状面骨折的分型与治疗[J]. 中华创伤骨科杂志, 2007, 9(2): 118-121.  
SHI Hong-fu, CAI Xian-hua, WANG Guo-dong, et al. Classification and treatment of the coronal fracture of the femoral condyle[J]. Chin J Orthopaedic Trauma, 2007, 9(2): 118-121.
  - [9] Hak DJ, Nguyen J, Curtiss S, et al. Coronal fractures of the distal femoral condyle: A biomechanical evaluation of four internal fixation constructs[J]. Injury, 2005, 36(9): 1103-1106.
  - [10] 汤亭亭, 戴克戎, 顾冬云, 等. 计算机辅助骨形态计量学分析系统的构建与应用[J]. 生物医学工程杂志, 2001, 18(4): 580-582.  
TANG Ting-ting, DAI Ke-rong, GU Dong-yun, et al. The development and application of computer-aided bone histomorphometry system[J]. J Biomed Eng, 2001, 18(4): 580-582.
  - [11] Dalle Carbonare L, Bertoldo F, Valenti MT, et al. Histomorphometric analysis of glucocorticoid-induced osteoporosis[J]. Micron, 2005, 36(7/8): 645-652.
  - [12] Scarano A, Degidi M, Iezzi G, et al. Maxillary sinus augmentation with different biomaterials: A comparative histologic and histomorphometric study in man[J]. Implant Dent, 2006, 15(2): 197-207.
  - [13] Thompson DM, Rohrer MD, Prasad HS. Comparison of bone grafting materials in human extraction sockets: Clinical, histologic, and histomorphometric evaluations[J]. Implant Dent, 2006, 15(1): 89-96.
  - [14] Sakakura CE, Nociti FH Jr, Mello GP, et al. Histomorphometric evaluation of a threaded, sandblasted, acid-etched implant retrieved from a human lower jaw: A case report[J]. Implant Dent, 2005, 14(3): 289-293.
- (本文编辑 王晴)